

Faculty of Dentistry



MSA

Faculty Of Dentistry



I would like to welcome our students and congratulate them for choosing, Faculty of dentistry at MSA university since you are highly distinguished students, this will impose a heavy burden on the faculty members but I assure that you will receive the best higher education backed by outstanding laboratory facilities, updated simulators, highly equipped clinics with the recent advanced equipment and e-learning system. This will give you the excellent opportunity to serve and treat your patients with the updated technology. You will also enjoy yourself with our social, cultural and sports activities.

Also the dental school offers the post graduate program for master degree in different fields of dentistry which is considered one of the best programs in the dental field.

I will assure to you that you will spend the most fruitful and enjoyable years of your life. We look forward to welcoming you to our faculty.

Professor/ Faten M. Kamel.

Dean of the Faculty of Dentistry.

Top Projects



IMPLANTS RETAINED MANDIBULAR OVER-DENTURE USING LOCATOR ATTACHMENT



**Menna Tallah
Abou-Zeid
142919**



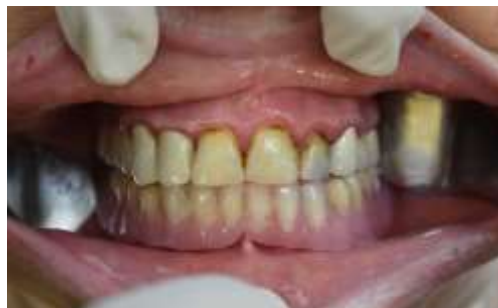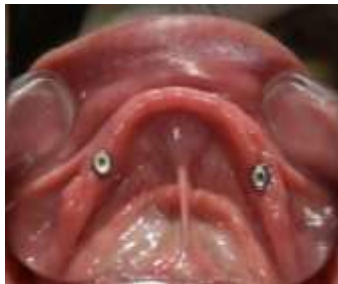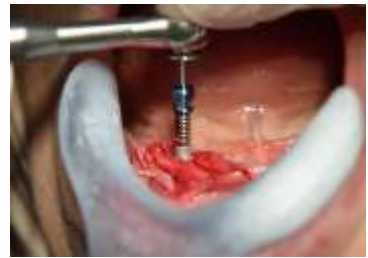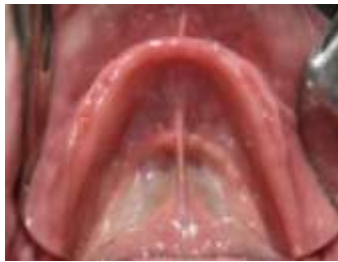**Ahmed Younis
144501**



**Tasneem
AbdelHafez
141985**

Abstract

A 52 years old female patient came to MSA clinics complaining from an ill-fitting lower single denture, opposed by bilateral fixed bridges. Radiographic examination through CBCT revealed adequate bone height and narrow width anteriorly. Implants were planned to be inserted bilaterally at the lower first premolar areas for their adequate width. Bilateral surgical flaps were reflected at the planned areas, and implants were inserted using the pre-fabricated surgical guide after sequential drilling. Implants left for 3 months for osseointegration, then Pick-up impression technique was made for the locator attachment to provide denture retention provided that it is accurately positioned regarding occlusion.



**Supervised by:
Ass.Prof.Samer Mostafa, Ass.Prof.Shereen Wagdy
& AL.Mohamed AbouHeikal**



**MULTIDISCIPLINARY APPROACH TO RESTORE
FUNCTION AND ESTHETICS FOR A PATIENT WITH
MAL-ALIGNED ANTERIOR TEETH AND MULTIPLE
MISSING AND CARIOUS DENTITION**



**Ahmed Hashem
142575**



**Hadir AbdelAal
144163**



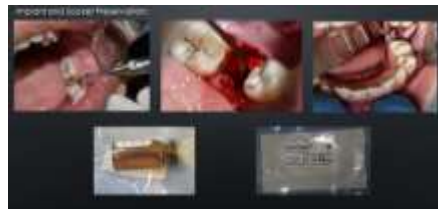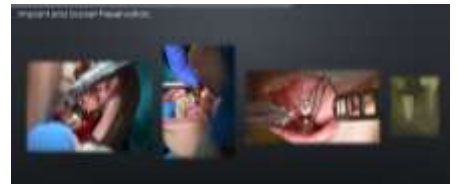
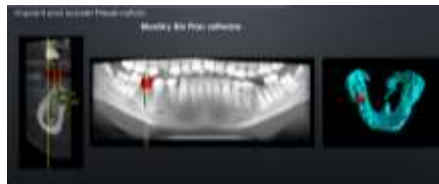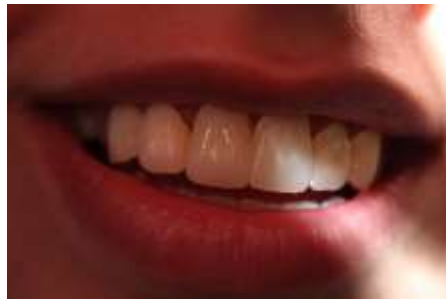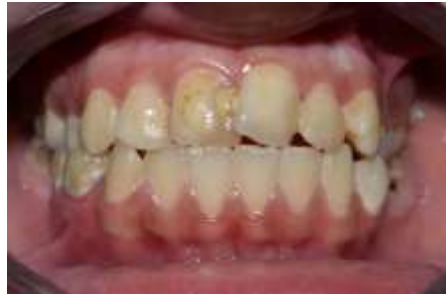**Fatma Hesham
145227**



**Abdelrahman
Genina
145583**

Abstract

In modern dentistry, there is an increased demand of perfect smile and pain-free, healthy oral environment. An 18 years old female patient with mal-aligned anterior teeth, multiple carious and missing teeth came to MSA clinic seeking a solution. After clinical and radiographic examination, full mouth rehabilitation was planned and achieved by Implant placement with bone graft, Operative treatment of the carious teeth, Endodontic treatment of non-vital teeth, and periodontal treatment followed by restoring normal alignment of anterior teeth using Digital Smile Design and virtual 3D dental designer. Finally, patient aesthetic satisfaction was obtained.



**Supervised by:
Dr.Ahmed Ebeid , Dr.Omnia Sultan, AL.Mohamed Abou
Heikal**

REHABILITATION OF ESTHETIC AND FUNCTION FOR SEVERELY CARIOUS AND MISSING TEETH USING IMMEDIATE IMPLANTS AND BONE GRAFT



Alaa Yasser
141793



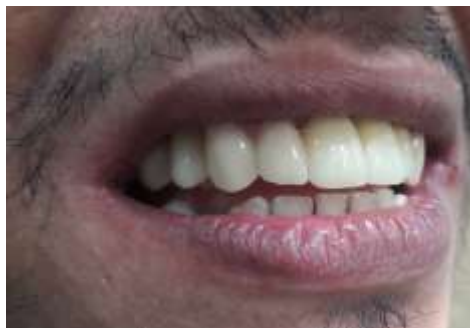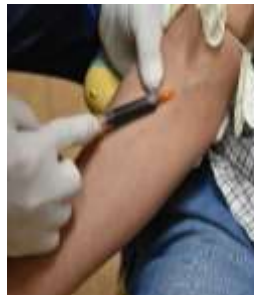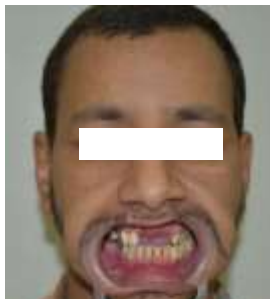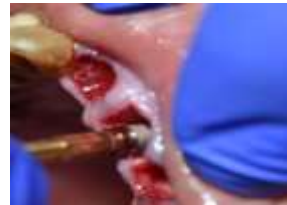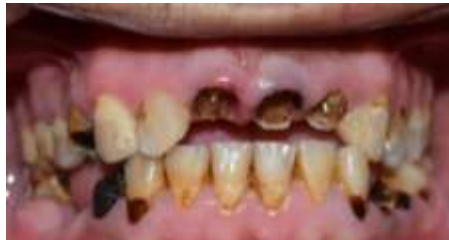Islam Basha
141819



Abdullah Awad
145327

Abstract

Smile design and esthetic dentistry has become a major concern among patients. A 31 years old patient came to MSA clinics to remove all the black decay and destructed teeth. All carious lesions were treated, endodontic treatment and retreatment in multiple teeth was performed. Finally, extraction of 6 non-restorable teeth was performed followed by immediate implant placement. Blood was withdrawn from the patient and Platelet Rich Fibrin (PRF) was prepared and used for grafting with one implant. Implants were left for 6 months for osseointegration to be finally restored by full coverage restorations. Mutilated teeth were restored by crowns and endo-crowns.



Supervised by:

**Ass.Prof.Shereen Wagdy, Ass.Prof.Heba Taher ,
AL.Mohamed AbouHeikal,AL.AbdAllah Mattar,
AL.Ahmed ElHawary & AL.Lamyaa ElFadaly**

**MULTIDISCIPLINARY APPROACH TO RESTORE
FUNCTION AND ESTHETICS OF A CASE WITH
AMELOGENESIS IMPERFECTA AND MALOCCLUSION
USING COMPLETE DIGITAL WORKFLOW**

Abstract

Restoring anterior teeth esthetics is one of the most challenging dental managements. A 24 years old male patient came to MSA Fixed prosthodontics clinics seeking a fixed bridge for anterior teeth. However, medical and dental history with clinical examination showed that he had Amelogenesis Imperfecta in the anterior region with extracted all four 1st permanent molars and 0.3mm deep bite due to traumatic enamel loss in the four anterior teeth. Digital planning (3 shape software) was used to plan for surgical and prosthetic treatment. Surgical bone augmentation using autogenous chin graft, implants placement, periodontal crown lengthening and full coverage crowns were made to restore function and esthetics.



**Karim Soliman
140055**



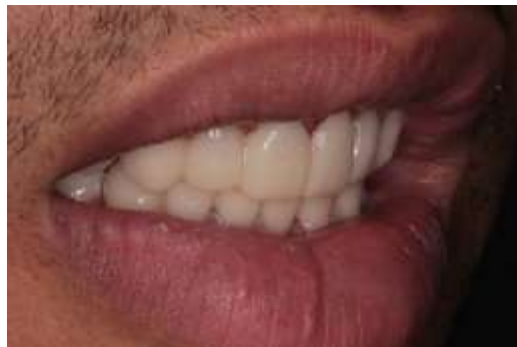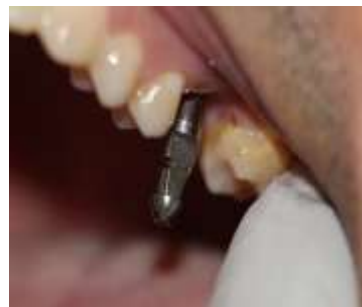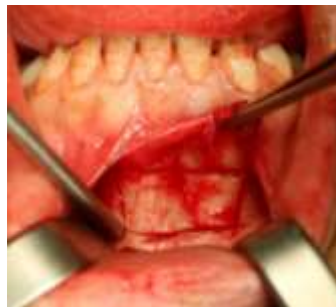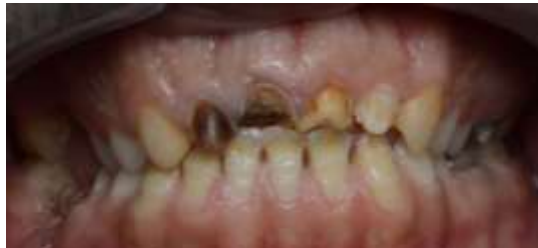**Fatema Maged
141033**



**Mohamed Abd
Elzاهر
141103**



**Hassan Omran
153887**



**Supervised by;
Dr.Omnia Sultan , AL.Mohamed AbouHeikal, AL.Ahmed
Wagdy, AL.Lamyaa EIFadaly & AL.Nada Zaazou**

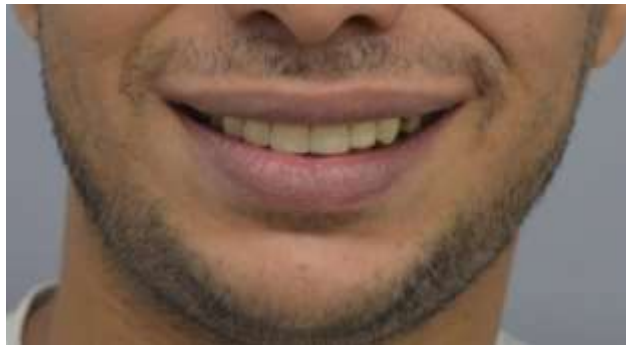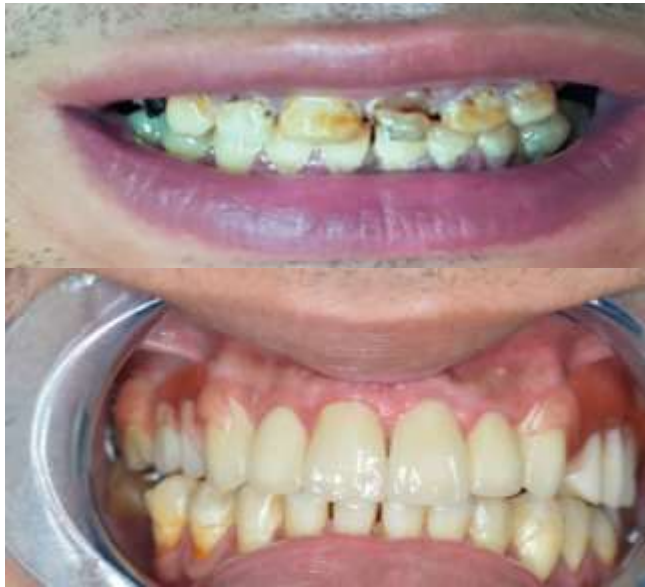ESTHETICS REHABILITATION OF SEVERELY DECAYED UPPER ANTERIOR TEETH



Amira Said
140841

Abstract

Nowadays, smile enhancement is considered a high demand to fulfill patient's smile fantasy. A 30 year old male patient presented to MSA clinics complaining from life time problem of anterior teeth. Clinical examination revealed multiple decayed teeth with old composite restorations, in addition to several missing teeth and remaining roots. Restoration of badly destructed upper anterior teeth was performed by root canal treatment, fiber post, composite core then all ceramic crowns. Upon radiographic examination using panorama and cone beam CT, implant were excluded as a treatment modality to restore posterior teeth so flexible denture was the treatment of choice.



Reham Al Afify
141713



Ahmed Badawi
141775



Supervised by:
Prof. Ahmed Hamdy, Ass.Prof Heba Taher,
AL.Lamyaa ElFadaly,AL.Mohamed Abou Heikal
& TA.Ihab ElMaghraby

THE USE OF ULTRASONIC TECHNOLOGY IN ENDO-SURGICAL PROCEDURES



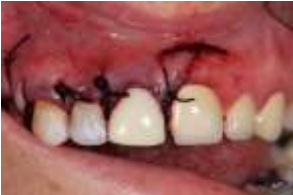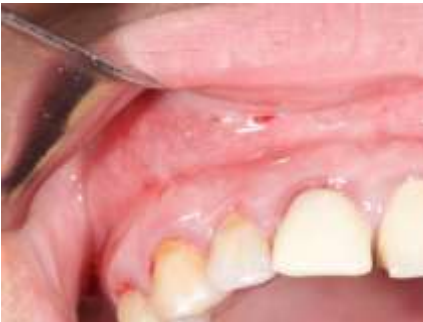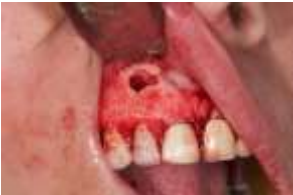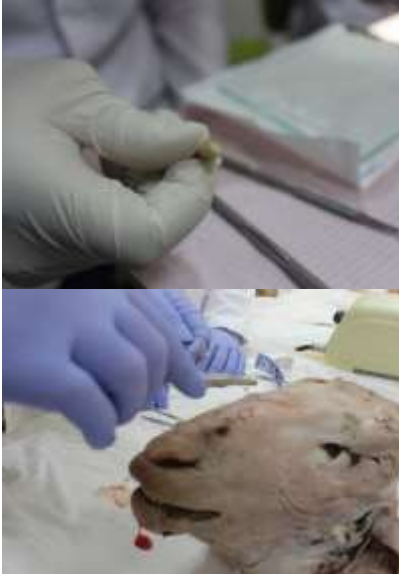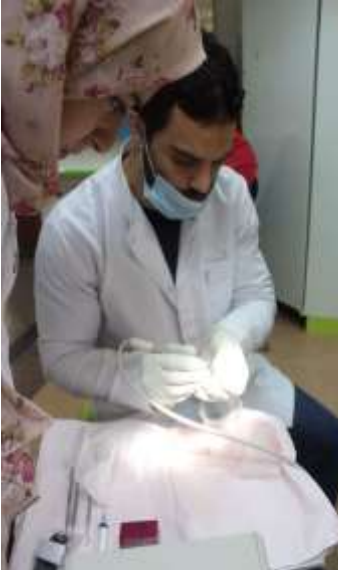Passant Ibrahim
141175

Abstract

A 50 years old patient came to MSA clinics with a swelling related to upper right lateral incisor tooth. After clinical and radiographic examination, a radiolucent lesion surrounding an overfilled canal by 3 mm was detected. Treatment plan was to perform apicectomy, and prepare the root canal for an MTA filling. Two workshops were held, one was on sheep head for surgical flap and suturing under supervision of Dr. Mohamed Hamdy, Ass. Lecturer of Oral & Maxillofacial Surgery. The 2nd one was on extracted teeth for ultrasonic tooth preparation under supervision of Dr. Hussein Shokry, Ass. Lecturer of endodontics. The surgical procedure, and MTA retrograde filling were then performed for the case.



Nourhan Ahmed
142857



Reem Khaled
140777



Supervised by:
Ass.Prof.Shereen Wagdy & Ass.Prof.Geraldine Ahmed

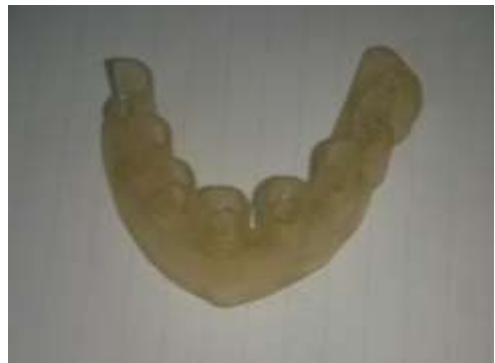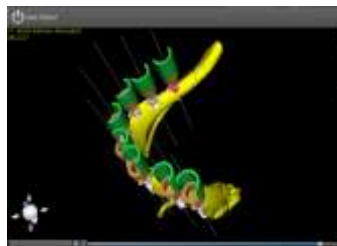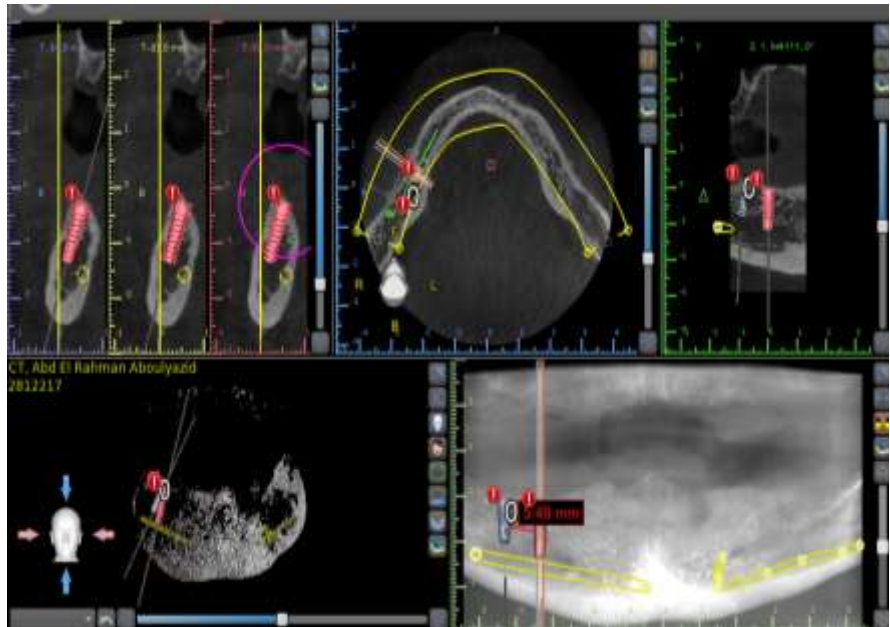
3D PLANNING OF IMPLANT PLACEMENT AND SURGICAL GUIDE FABRICATION

Abstract

The 3D technology has become an effective tool in the field of dentistry. The aim of this project was to assess the use of 3D virtual planning and 3D printing for the rehabilitation of edentulous mandible by dental implants. By the aid of Blue Sky Bio software, the pre-operative 3D virtual planning was performed. The surgical plan was to place 8 dental implants in the edentulous mandible to support a fixed prosthesis. A surgical guide was virtually constructed according to the pre-operative planning, printed, and sterilized to be used in the surgery.



**Osama Abd El
Fattah
141227**



**Mario Helmy
142305**

**Supervised by:
Prof.Nader El Bokle & Ass.Prof.Shereen Wagdy**



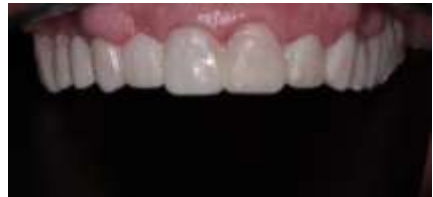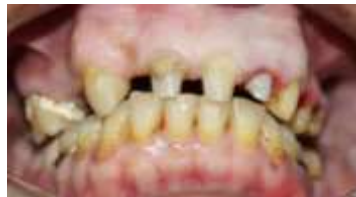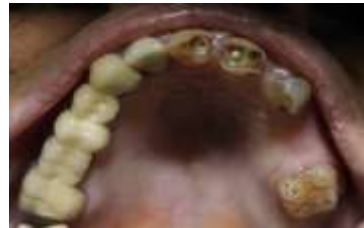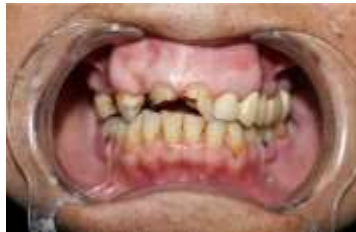CORRECTION OF THE OCCLUSION AND VERTICAL DIMENSION OF OCCLUSION WITH ESTABLISHING ESTHETICS AND FUNCTION.

Abstract

A 62 years old female patient came to MSA clinics complaining of inability to eat and poor aesthetics. Clinical and radiographic examination revealed fractured anterior teeth, multiple missing teeth and multiple decayed posterior teeth. The aim of this project was the functional and esthetic rehabilitation of the patient's dentition. This target was achieved through meticulous face bow and centric relation records along with minimal raise in vertical dimension of occlusion (VDO). To restore the esthetic aspect, several modifications of mock-up were made and the most suitable one was constructed, taking into consideration the patient's facial dimensions. Finally, Fixed Porcelain Fused to Metal (PFM) prosthesis with a harmonious occlusion was constructed.



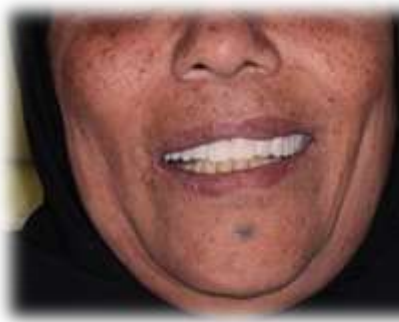Youmna Abd El-Hadi
140925



Basma Mahmoud
141453



Basma Ezzat
144365



Supervised by:
Prof.Ahmed Hamdy, AL.Faisal Hamza, TA.Ihab El Maghraby

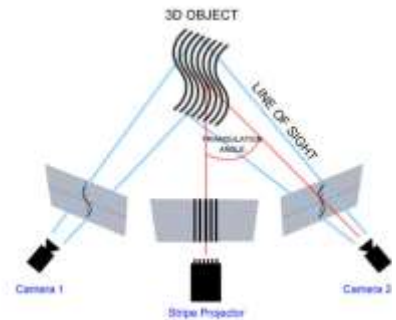
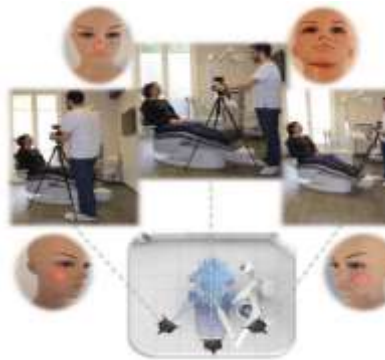APPLICATIONS OF STERIPHOTOGRAMETRY IN ORAL & MAXILLOFACIAL SURGERY

Abstract

The aim of this project was to discuss the applications of stereophotogrammetry in dentistry. Obtaining of 3D images was previously done through taking 2 images of the same object by moving the camera to the other side without changing the level of imaging. Nowadays by the evolution in imaging, 3D image has become much easier. The 3D laser scanning and digital cameras along with software as 3DMD or Genex system are now used. This technology is used in maxilla-facial reconstructions, evaluating the abnormality of malformed craniofacial features, 3D model fabrication, Orthognathic surgery and Forensic identification.



Ibrahim Ahmed
141281



Essam-El-Din
Esmat
141531



Supervised by:
Prof.Nader ElBokle & Dr.Omnia Sultan





Ahmed Mansour
134961



Tarek Al-Agamawy
140741



Reem Abd El-Hameed
140777



Mohamed Zein Aldin
141111



Passant Ibrahim
141175

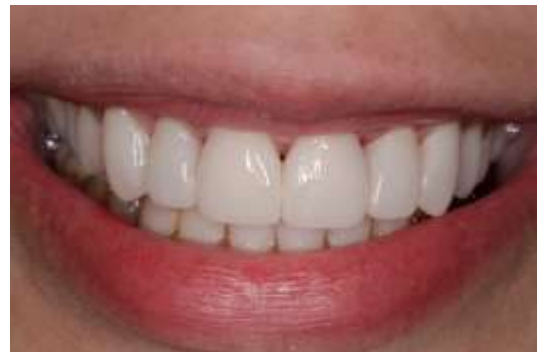
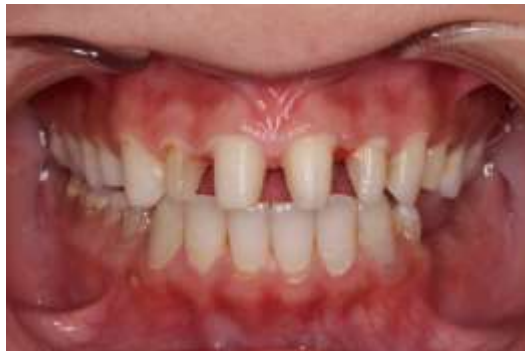
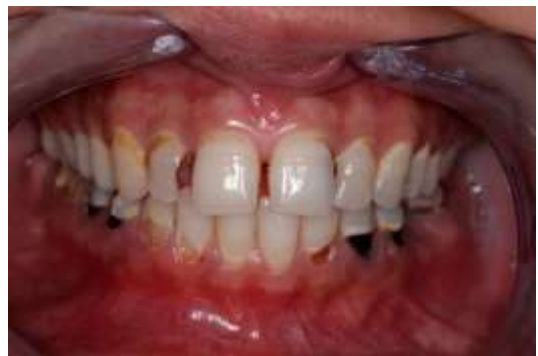Nourhan Ahmed
142857

FULL MOUTH REHABILITATION AND ESTHETIC RESTORATION OF SEVERELY MUTILATED TEETH

Abstract

A 22 years old female patient presented to MSA clinics with bad oral hygiene, badly decayed teeth, and remaining roots. A treatment plan was set to restore both function and esthetics. The treatment plan started with periodontal therapy, followed by conservative therapy to restore all the badly decayed teeth. Then endodontic therapy was performed in all non-vital teeth. Furthermore, prosthetic therapy was performed. Surgical plan involved surgical extraction of non-restorable teeth, and implant placement. Virtual planning using Blue Sky Bio program was used to guide to the perfect alignment of implants, bone density measurements and finally surgical guide fabrication which was then 3D printed to be used in surgery.



Supervised by:
Prof. Ahmed Hamdy, Prof. Heba Taher
& AL.Mohamed Khalil

3D VIRTUAL PLANNING IN ORTHOGNATHIC SURGERY



Mohammed Saleh
141153



Momen Sherif
145329

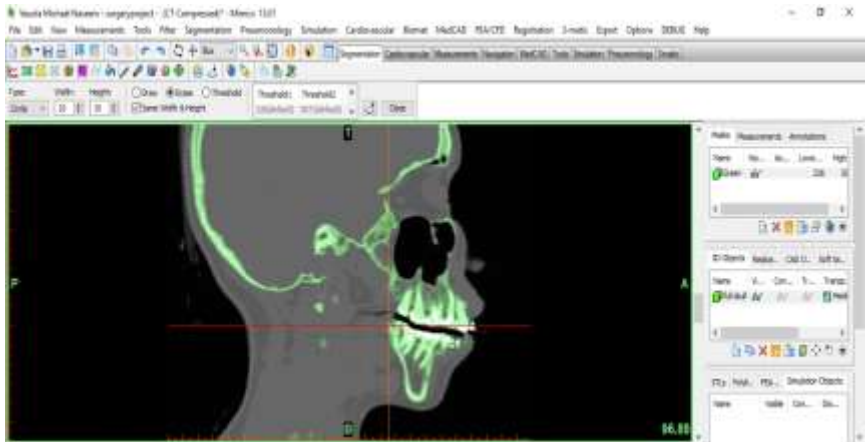
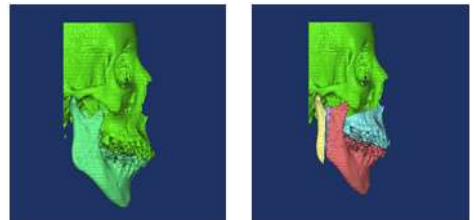
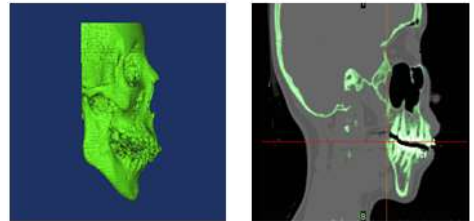
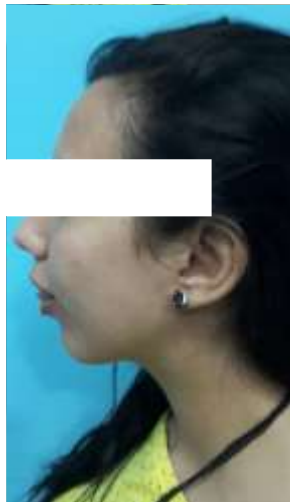

Ahmed Soliman
145345



Abstract

3D virtual planning (VP) has become an effective diagnostic tool in orthognathic surgery. In the following case 3D VP was compared to traditional technique in pre-operative surgical planning of orthognathic surgery. Mimics software was used to perform the planning, segmentation, and 3D printing of surgical splints. The reported case was for 22 years old female patient who complains from gummy smile and skeletal problem. The pre-operative surgical planning was to perform maxillary impaction and mandibular advancement to correct the gummy smile and final occlusion.



Supervised By:
Prof.Nader ElBokl & Ass.Prof.Ingy Chehata

Post-Graduate Projects



The Efficacy of Contemporary p(NIPAM)- based Microgel particles on Sealing ability & Shear Bond Strength to Dentin Compared to Universal Bonding System: An In vitro study

Abstract

This study was conducted to determine the effectiveness of polymeric microgel dialyzed anionic p(NIPAM) on sealing of dentinal tubules, it also evaluated the influence of the use of the polymer p(NIPAM) on the bond strength to dentin. It was concluded that p(NIPAM) can be used with adhesive system without affecting the bond strength. Moreover, The etch and rinse adhesive could not resist degradation under thermal conditions. Furthermore, the addition of p(NIPAM) might be able to protect the adhesive interface against degradation when subjected to clinical thermal conditions.



**Ruba El
Damarisy**

**TA of
Conservative
dentistry**

MSA University

Supervisors

Prof.Dr. Faten Kamel,

**Professor of conservative dentistry
Dean of faculty of dentistry ,MSA University**

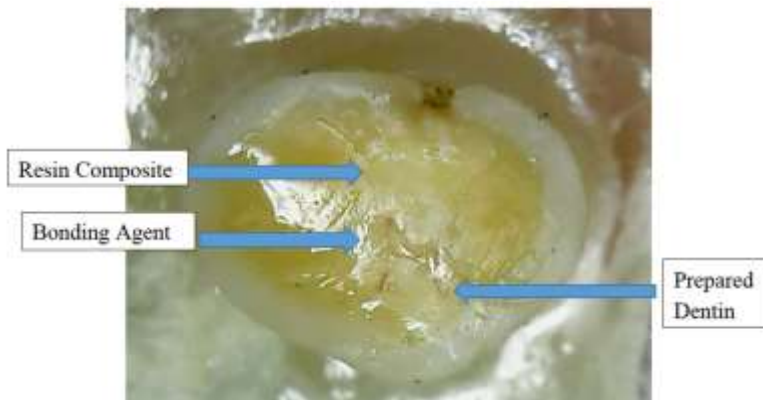
Dr. Reham Mohsen

**Assistant professor of Biotechnology, MSA Univeristy
Researcher at Greenwich University**

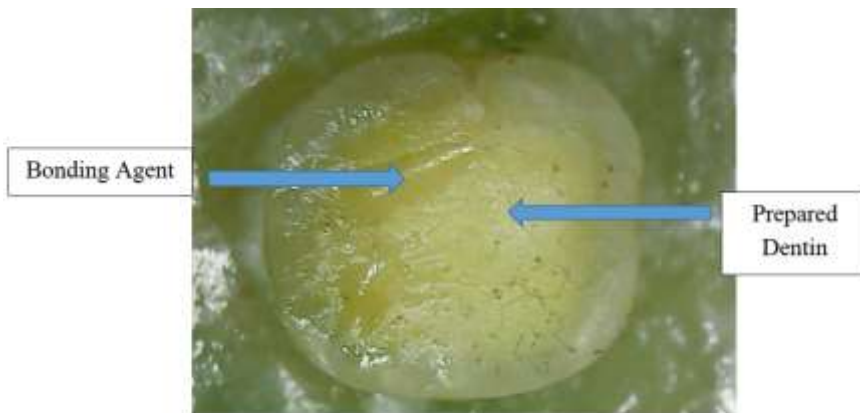
Dr. Mona Fadel

Lecturer of conservative dentistry,MSA University

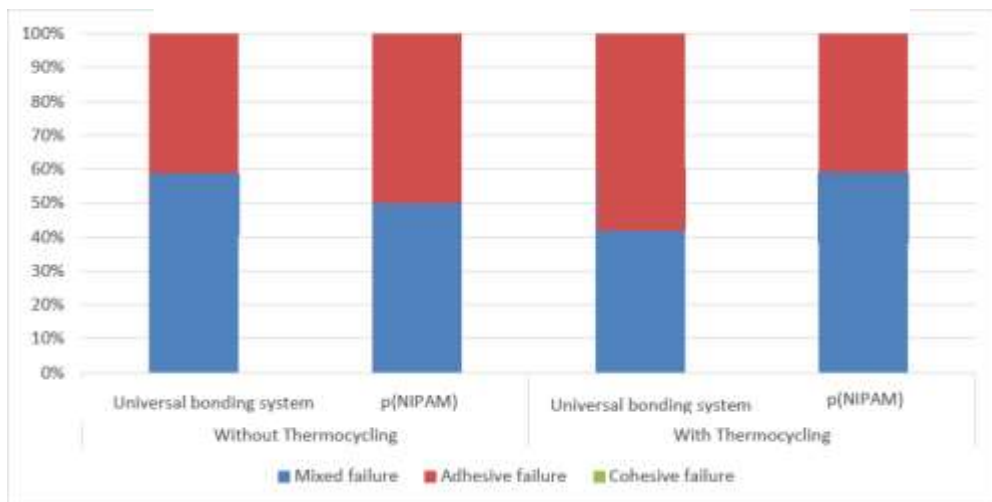




Digital photograph showing mixed fracture for universal bonding system without thermocycling (AT0) group



Digital photograph showing adhesive fracture for p(NIPAM) without thermocycling (BTO) group



Histogram showing the percentage of different modes of fracture before and after thermocycling for the two different groups.

Antimicrobial Efficacy of Silver Nanoparticles Using Poly(NIPAM) Based Microgel Particles as a Drug Delivery System against Enterococcus faecalis (An In-Vitro Study)

Abstract

This study aims at comparing the intracanal medication efficacy of poly(NIPAM) when used alone or in combination with silver nanoparticles against *Enterococcus faecalis*. The secondary aim is to observe the structural integrity of the biofilm on the dentin surface. Methods: The MIC and MBC of p(NIPAM) (X), p(NIPAM) with AgNP (Y), and AgNP (Z) were determined by two-fold serial dilution (0.312 mg/mL - 10 mg/mL). Thirty-nine extracted permanent maxillary teeth were gathered, prepared, and contaminated with *E. faecalis*. Teeth were split into 4 main groups for exposure; 12 in each X, Y, and Z groups, and 3 teeth as a positive control. Groups X, Y, and Z were split into subgroups based on material exposure time; 1 day and 7 days. Two samples from each subgroup was sectioned longitudinally and prepared for observance under scanning electron microscope. Microbial samples were taken for the rest of the samples. The CFU was counted and compared to the control. The Kruskal-Wallis test compared the study parameters among the groups at 1 day and 7 days ($p < 0.05$). Results: The MBC of the AgNPs was 10 mg/mL. For the teeth, samples showed that the AgNP group had the most significant results after 7 days, with a p-value of 0.03. In the presence of p(NIPAM) constriction of the dentinal tubules was found. Significance: AgNPs have shown to be effective against *E. faecalis* and further studies is needed on the antibacterial potential of p(NIPAM) on *E. faecalis*.

Supervisors

Prof. Dr. Manar Yehia Fouda

Professor of Endodontics

Faculty of Dentistry, Cairo University

Dr. Mohamed Yehia Hassan,

Lecturer of Endodontics, MSA University

Dr. Reham Mohsen

Assistant professor of Biotechnology, MSA University

Researcher at Greenwich University




Nedda Elsayed

**TA of Removable
Prosthodontics**

MSA University





Photograph of Plate Streaking (MBC)

1= 5 mg/mL 2= 2.5 mg/mL

A- Streaking of three different concentrations of Group X (p(NIPAM)).

X10= 10m g/mL

B- Streaking of three different concentrations of Group Y (p(NIPAM) + AgNP).


Y10= 10 mg/mL

C- Streaking of three different concentrations of Group Z (AgNP).

Z10= 10 mg/mL



Photograph of saline solution



SEM of middle root canal wall exposed to 10 mg/mL p(NIPAM) microgel after 1 day (x5000)

MARGINAL DISCREPANCY AND FRACTURE RESISTANCE OF THE TWO ENDOCROWN PREPARATION DESIGNS (BUTT-JOINT/FINISH LINE) USING TWO ADHESION PROTOCOLS. IN VITRO STUDY

Abstract

This study was designed to evaluate fracture resistance and marginal discrepancy between two endocrown preparation designs using two adhesive protocols. It was concluded that Preparation design for endocrown could significantly influence the fracture resistance after thermocycling. Both designs showed greater value than normal masticatory force. Moreover, In order to get significant higher fracture resistance with finish line preparation design for endocrown use etch and rinse cement rather than self-adhesive cement. Furthermore, using self-adhesive cement with butt joint design preparation of endocrown restoration showed significant higher fracture resistance than etch and rinse cement. Finally, In case of high stress areas on the endocrown restoration it is preferable to use endocrown restoration with finish line design cemented by etch and rinse cement.




Ahmed Arabi



Supervisors

Prof.Dr.Rabab Mohamed Ibraheem
Professor of Fixed Prosthodontics
Faculty of Dentistry,Cairo University


Dr.Ahmed Ebeid
Lecturer of Fixed Prosthodontics
MSA University



Testing fracture strength



Thermocycling



Measuring marginal gap



Measuring marginal gap

EVALUATING FRACTURE RESISTANCE and MARGINAL INTEGRITY of CRYSTAL ULTRA CERAMIC RESIN HYBRID MATERIAL COMPARED to E.MAX- IN VITRO STUDY

Abstract

Hybrid Ceramics have been recently introduced where ceramics have been combined with composite resins to solve the brittleness property of ceramics as well as providing modulus of elasticity close to that of dentine. A newly launched hybrid restorative material claimed to be the strongest restorative material in terms of compressive and flexural strength. The purpose of this study was designed to compare the marginal integrity and fracture resistance of 3-unit e.max and Crystal Ultra FDP after thermocycling. Conclusion: Crystal Ultra Fixed Dental Prosthesis presented statistically higher mean marginal integrity values after aging than the IPS e.max CAD group. Fracture resistance of IPS e.max CAD group displayed statistically significant higher mean value than the Crystal Ultra group.



Christine Henry

TA of Fixed
Prosthodontics

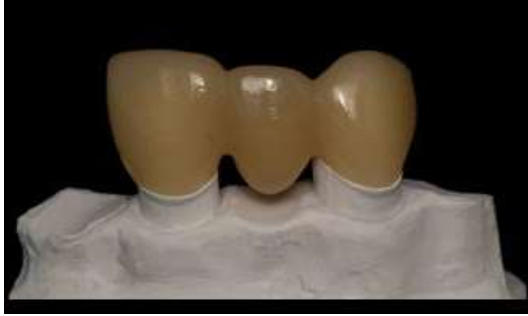MSA University



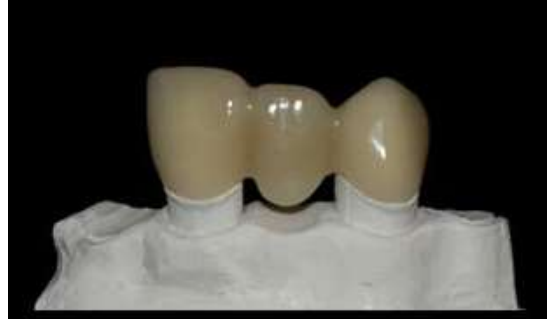Supervisors

Prof.Dr.Nadia Fahmy
Professor of Fixed Prosthodontics
MSA University

Dr.Ahmed Ebeid
Lecturer of Fixed Prosthodontics
MSA University



Crystal Ultra
Fixed Dental Prosthesis



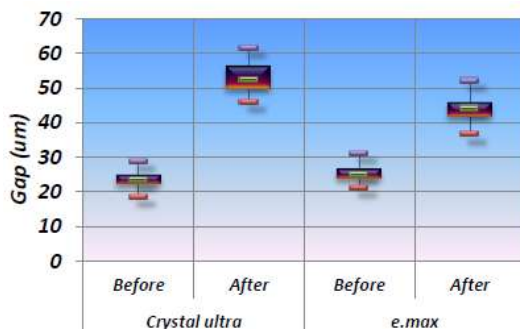
IPS e.max
Fixed Dental Prosthesis



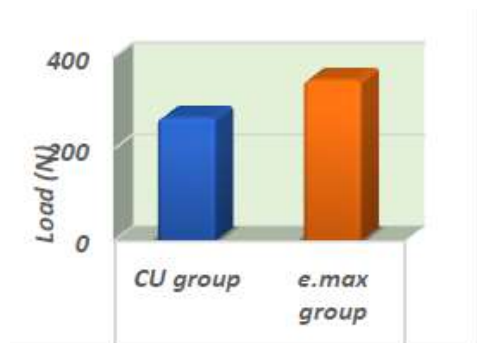
Marginal Gap Evaluation



Fracture Resistance
Testing



Box plot of marginal gap mean values for both ceramic groups before and after thermal aging



Histogram showing fracture resistance results mean values for both groups after thermal aging